

## Medial Gastrocnemius Flap for Covering Tissue Defects Around the Knee

Liabakh A.P., Lazarenko H.M., Kulieva O.V.

SI "Institute of Traumatology and Orthopedics of NAMS of Ukraine", Kyiv

**Summary.** Tissue defects of the anterior surface of the lower leg and the knee joint is a severe problem at the treatment of orthopedic patients. **Objective.** Analysis of the results of using the medial gastrocnemius flap (MGF) in orthopedic patients; highlighting peculiarities of surgical technique. **Materials and Methods.** 8 patients (10 cases) who underwent the transposition of the MGF. The age of the patients was 19–74 years (on average  $40.5 \pm 5.7$  years); there were 6 males and 2 females. The list of cases: open fractures – 2 cases, combat injury – 2 patients (3 cases), skin necrosis after osteosynthesis – 3 patients (4 cases), and skin necrosis after total knee replacement – 1 case. The results of treatment were assessed in terms 9 months – 10 years by the Lysholm scale. **Results.** Autodermoplasty during MGF transposition was performed in two cases and after a few days in others. In cases with open fractures, the osteosynthesis and external fixators reassembly were done; conversion of osteosynthesis was performed one month after autodermoplasty. In cases of skin necrosis after osteosynthesis and total arthroplasty, the implants were never removed. Knee function according to the Lysholm scale ranged from 70 to 100 points (mean  $88.2 \pm 3.3$ ). **Conclusions.** The transposition of the MGF for the replacement of tissue defects of the anterior surface of the lower leg and knee joint is an effective method in orthopedic surgery, which helps to solve the problem of infectious complications and to save the supporting-kinematic function of the lower extremity.

**Key words:** lower leg; medial gastrocnemius flap; open fracture; tissue defect.

### Introduction

The anterior surface of the upper third of the tibia and knee joint is covered with inelastic skin and a thin subcutaneous tissue, which are close to the underlying bone. Tissue defects in this area occur due to various reasons: trauma, complications during arthroplasty, treatment of tumors, etc.

Timely and adequate closure of the tissue defect in this area is decisive for maintaining the function of the knee joint, and in some cases – for preserving the lower limb. Since Mathes S.J. and Nahai F. [1] established the anatomical possibilities of using the medial head of *m.gastrocnemius* as an island flap for covering tissue defects of the anterior surface of the upper third of the lower leg, this surgical technique is successfully used in traumatological and oncological cases [2–4]. Significant advantages of the medial head of *m.gastrocnemius* (medial gastrocnemius flap – MGF) are permanent vascular anatomy, simple elevating technique, mobility, and minimal loss of the donor site [5].

This study was carried out to analyze the outcome of using a medial gastrocnemius flap in orthopedic and traumatological patients, and to highlight peculiarities of surgical technique.

### Material and Methods

This study was carried out at the Department of Foot Pathology and Complex Prosthesis (SI "Institute of Traumatology and Orthopedics of NAMS of Ukraine") in accordance with the Declaration of Helsinki (1975), as revised in 2008. Informed consent was taken from all the patients.

Eight patients (10 cases) who underwent MGF transposition were under our observation. The age of the patients was 19–74 years (on average  $40.5 \pm 5.7$  years); there were 6 males and 2 females. The indication for MGF transposition was a tissue defect on the anterior surface of the knee and upper third of the lower leg, which topographically corresponded to the area from the lower pole of the patella to the border of the proximal and middle third of the lower leg. The detailed characteristics of patients are presented in Table 1.

**Surgical technique.** Prevention of thromboembolic complications and antibiotic therapy was carried out according to the current hospital guidelines. The patients were operated on under general or spinal anesthesia in the supine position; it was obligatory to use a tourniquet at the level of the inguinal fold.

The initial stage included: recipient wound debridement, revision of pockets and heats, and repeated wash-

Table 1

**Clinical characteristics of patients enrolled in the study**

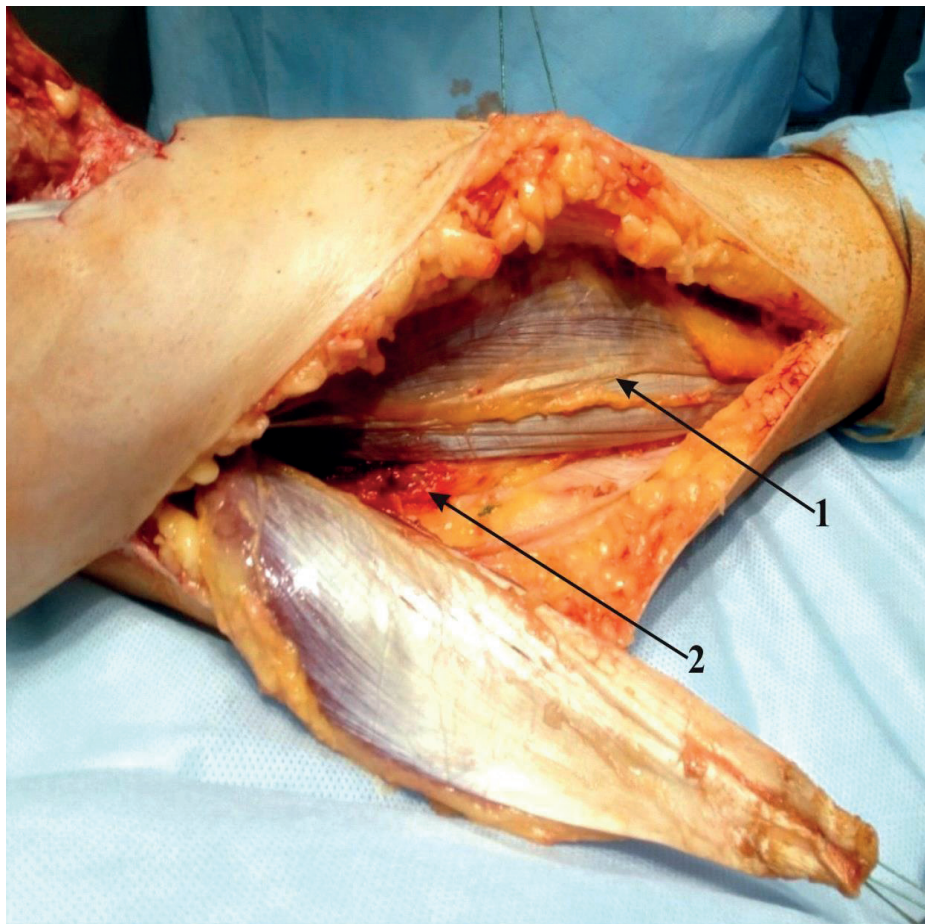
No	Diagnosis	Sex	Age	Time since injury/ complication	Orthopedic component of reconstruction	Knee function after surgery according to the Lysholm scale
1.	AO 41 A3 G-A II	f	19	48 hrs	Internal&External fixation	100
2.	AO 41 A2 G-A IIIA	m	44	72 hrs	External fixation	100
3.	AO 41 C2 Skin necrosis after surgery	m	35	24 hrs	None	83
4.	AO 41 C2 Skin necrosis after surgery	m	35	24 hrs	None	83
5.	AO 41 C2 Skin necrosis after surgery	m	50	24 hrs	None	98
6.	Mine-blast injury AO 41 A2 G-A IIIB	m	23	1 week	Reassembly of external fixation, osteosynthesis conversion	82
7.	Mine-blast injury AO 41 C2 G-A IIIB	m	23	1 week	Reassembly of external fixation, osteosynthesis conversion	83
8.	Gunshot injury AO 41 C2 G-A IIIB	m	37	2 weeks	Reassembly of external fixation, osteosynthesis conversion	100
9.	AO 41 C3 Skin necrosis after surgery DM type II	f	65	48 hrs	None	83
10.	Oncological total knee arthroplasty, skin necrosis after surgery	f	74	1 week	None	70

Note: AO – Association of Osteosynthesis, classification of fractures  
 G-A – the degree of tissue damage according to Gustilo-Anderson  
 DM – diabetes mellitus

ing. Elevation of MGF was carried out according to the described methods. The patient was in the supine position with the leg bent at the knee joint with slight external rotation. Direct access along the medial edge of the *m. gastrocnemius* from the *popliteal fossa* to the Achilles tendon was: 2–3 cm posteriorly to the posterior edge of the tibia if the muscle will move directly into the defect; 6–7 cm posteriorly to the posterior edge of the tibia if the muscle was planned to be carried out in the subcutaneous tunnel. After skin incision, *v. saphena magna* was isolated and taken on a holder. The fascia of *m. gastrocnemius* and *m. soleus* was cutted and muscles were divided in such a way that the tendon of *m. plantaris* passed together with *m. soleus*. On the ventral surface, an interval was found between the medial and lateral heads of *m. gastrocnemius*; *n. cutaneus surae medialis* and *v. saphena parva*, which are located lateral to the midline at the level of the muscle-tendon junction, were identified between them. The medial head was cut from the Achilles tendon so that the distal end of the flap contained approximately 1 cm of tendon tissue. The tendon cuff was sutured and the medial head was cut off from the lateral

one, *n. cutaneus surae medialis* and *v. saphena parva* departed together with the lateral head. The flap preparation was continued up to the *popliteal fossa*, where the neurovascular pedicle of the medial head was identified (*a. surae medialis*, *vv. comitantes*, *n. motoricus*). In most cases, there was no need to isolate the neuro-vascular pedicle to increase the mobility of the flap (Fig. 1).

The flap lifting was completed; the flap was moved into the defect directly or in the tunnel under the skin bridge. Excessive tension, bending, and twisting of the flap were strictly avoided. To place the distal end of the flap, the corresponding edge of the recipient wound was mobilized, and the tendon part of the flap was sewn into this “pocket”; the ends of the thread were brought out onto the skin. The flap was placed in the recipient site in such a way that the edges of the skin covered it by 0.5–1 cm from all sides. Drainages were installed: one in the donor site, the second under the flap. All skin wounds were sutured. The flap was rather tightly sewn over the epimysium to the edges of the skin wound. The covering of the muscle was performed with split-thickness or whole-layer skin flap immediately or a few days after the surgery.



**Fig. 1.** The view of donor wound after the MGF elevation completed:  
1 – *m. plantaris* Tendon; 2 – *n. surae medialis, v. saphena parva*

Fractures were stabilized with external fixators; in cases where preventive external fixation had already been performed, the external fixator was reassembled to free the knee joint. After healing of postoperative wounds (on average, 3–4 weeks after autodermoplasty), internal osteosynthesis and bone grafting were performed.

The results of treatment were assessed in terms of 9 months – 10 years using the Lysholm scale.

## Results

The course of the postoperative period in all cases was uncomplicated. Autodermoplasty during MGF transposition was performed in two cases, and a few days after the surgery in others. In cases of combat trauma, the MGF transposition was combined with the external fixator reassembly to free the knee joint. Conversion of osteosynthesis was carried out 1 month later by locking plate and substitution of the tibia defect by allogenic bone.

In cases when osteosynthesis was complicated by skin necrosis in the postoperative period, the knee joint was immobilized with an orthosis for two weeks after the MGF transposition.

The outcomes of treatment were assessed within 9 months – 10 years; full weight-bearing function of the lower limb was restored in all cases (Fig. 2). Knee function according to the Lysholm scale ranged from 70 to 100 points (mean  $88.2 \pm 3.3$  points).

## Discussion

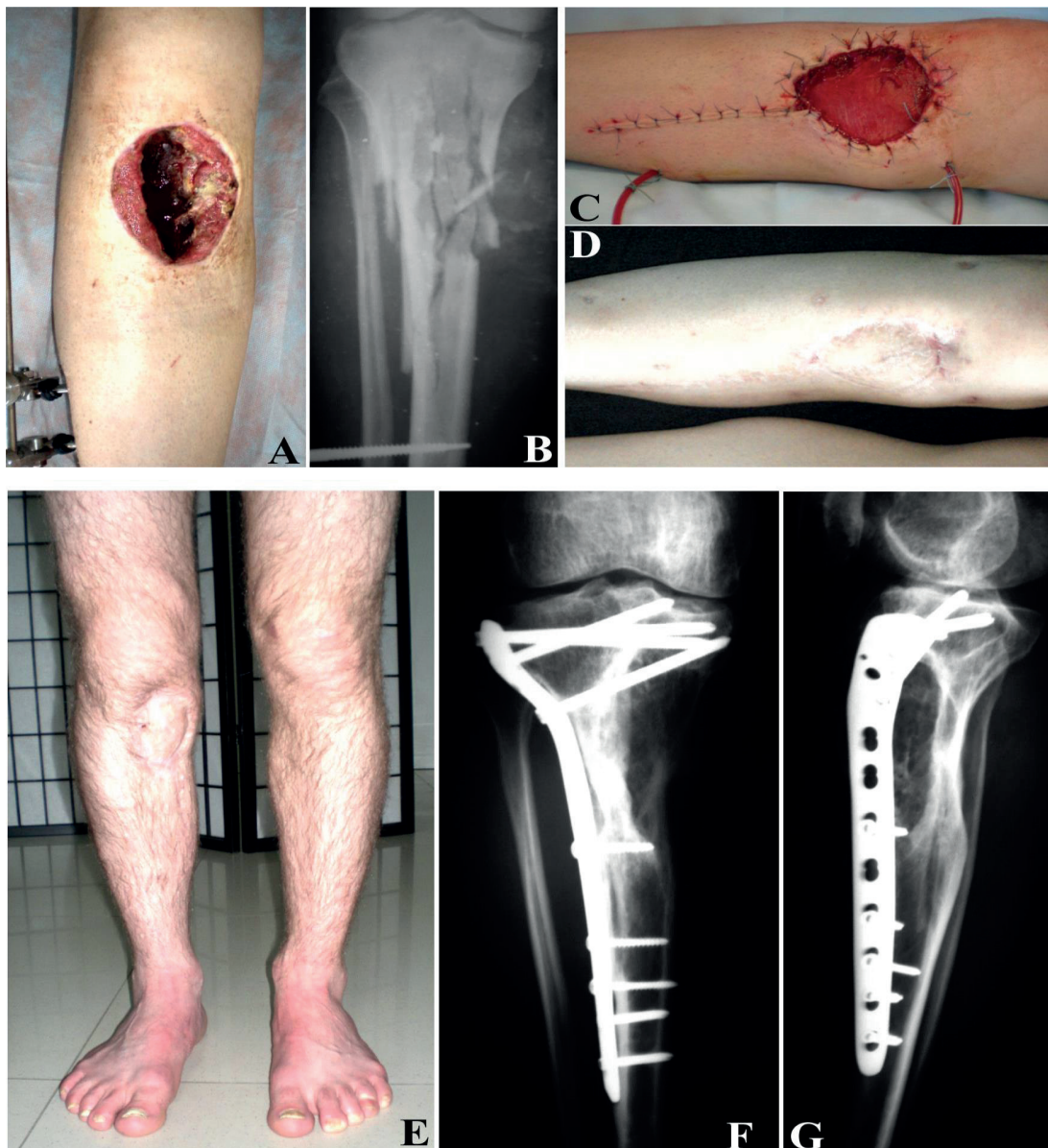Island MGF is one of the most used flaps in severe trauma of the upper third of the lower leg and complications after reconstructive surgery around the knee, i.g. total knee arthroplasty. Stable vascular anatomy, simple surgical technique, and the ability to close a section of the knee joint and the proximal third of the lower leg make MGF indispensable for open injuries of this area and skin complications of traumatic and another genesis.

*M. gastrocnemius* has a unique vascular anatomy: each of its heads has its own neurovascular pedicle about 5 cm long. Both pedicles starting slightly proximal to the knee joint [1]. The most commonly used is medial head of *m. gastrocnemius*, which in adults has the following dimensions: 15–20 cm length and about 8 cm width [1].

Skin and soft tissues defects along the anterior surface of the knee joint and the proximal part of the leg resulting from trauma and other situations, require early closure due to the risk of osteomyelitis, loss of function of the knee joint and even amputation [6]. In particular, with open fractures of the proximal tibia, the infection of the surgical site can reach 45% [7]. According to a meta-analysis of Henkelmann R. et al. [6], in 55.8% of cases, after open fractures of the proximal tibia, various complications occur, of which the most important are non-union and pseudarthrosis (15.3%), stiffness and ankylosis of the knee joint (18.7%), and limb amputation (5.4%).

A combat injury of the lower limb, especially mine-blast injury with smaller devices, is probably the most difficult problem for achieving acceptable anatomical and functional treatment results. One of the important points is the adequate debridement of devitalized tissues, which almost always causes a tissue defect of the lower leg [8].

Early and reliable closure of a soft tissue defect in some cases allows preserving a functioning limb [3]. Among our observations, there were 3 such cases; the use of MGF made it possible to carry out adequate control of infection in the early stages of treatment, which enabled further orthopedic reconstruction (Fig. 2).



**Fig. 2.** Gunshot wound to the right lower leg (2015). Specialized assistance – surgical debridement and external fixation of the thigh–lower leg. After 2 weeks, necrectomy and replacement of the tissue defect with the MGF; autodermplasty after 5 days. After 1 month, metal osteosynthesis with a locking compression plate and substitution of the tibia defect by allogenic bone graft. A and B – view of the wound and X-ray of the lower leg 2 weeks after the injury; C – after MGF transposition; D – a month after autodermplasty; E, F, G – view of both lower limbs and X-rays of the right lower leg 1 year after osteosynthesis and bone grafting

Fractures with traumatized but visually intact skin are especially difficult for treatment. Under such conditions, after osteosynthesis, necrosis of skin flaps can occur with exposure of bone and fixators. Recommendations for such cases in the modern literature include: necrectomy, vacuum assisted closure (VAC), and MGF transposition [9]. Among our observations, there were 4 similar cases. We applied one-step closure of the defect after necrectomy and got healing without complications.

Tetreault M.W. et al. [4] believe that the use of MGF is the best solution for infection after total knee arthroplasty due to skin necrosis, both to preserve the existing implant and in a two-stage procedure using a spacer. Their publication highlights the largest case series (31 patients) in the English-language literature. Among our observations, there was one similar case in a 74-year-old patient after oncological endoprosthesis.

## Conclusion

MGF transposition for replacing tissue defects in the anterior surface of the lower leg and knee joint is an effective technique in orthopedic and traumatological practice, which allows solving the problem of infectious complications and preserving the musculoskeletal function of the lower limb. Stable vascular anatomy, simple surgical technique, and sufficient predictability of treatment results allow recommending this technique for wider application.

**Conflict of interest.** The authors declare no conflict of interest. This publication has not been, is not and will not be the subject of commercial interest in any form.

## References

1. Mathes SJ, Nahai F. Classification of the vascular anatomy of muscles: experimental and clinical correlation. *Plast Reconstr Surg.* 1981; 67(2):177-87. PMID: 7465666.
2. D'Avila F, Franco D, D'Avila B, Arnaut M, Jr. Use of local muscle flaps to cover leg bone exposures. *Rev Col Bras Cir.* 2014; 41(6):434-9. DOI: 10.1590/0100-69912014006009.
3. Ebrahimi A, Nejad Sarvari N, Ebrahimi A, Rasouli HR. Early reconstructions of complex lower extremity battlefield soft tissue wounds. *World J Plast Surg.* 2017; 6(3):332-42. PMID: 29218283.
4. Tetreault MW, Della Valle CJ, Hellman MD, Wysocki RW. Medial gastrocnemius flap in the course of treatment for an infection at the site of a total knee arthroplasty. *JBJS Essent Surg Tech.* 2017;7(2):e14(1-13).
5. Veber M, Vaz G, Braye F, Carret JP, Saint-Syr M, Rohrich PJ, Mojallal A. Anatomical study of the medial gastrocnemius muscle flap: a quantitative assessment of the arc of rotation. *Plast Rec Surg.* 2011; 128(1):181-7. DOI: 10.1097/PRS.0b013e318217423f.
6. Henkelmann R, Frosch KH, Glaab R, Lill H, Schoepp C, Seybold D et al. Infection following fractures of the proximal tibia - a systematic review of incidence and outcome *BMC Musculoskelet Disord.* 2017;18(1):481. DOI: 10.1186/s12891-017-1847-z.
7. Choo KJ, Morshed S. Postoperative complications after repair of tibial plateau fractures. *J Knee Surg.* 2014; 27(1):11-19. DOI: 10.1055/s-0033-1363517.
8. Doucet JJ, Galarneau MR, Potenza BM, Bansal V, Lee JG, Schwartz AK et al. Combat versus civilian open tibia fractures: the effect of blast mechanism on limb salvage. *J Trauma* 2011; 70:1241-7. DOI: 10.1097/TA.0b013e3182095b52.
9. Cui H, Xiao H, He K, Peng Y, Bian Z, Wang H. V-Y advancement of medial gastrocnemius muscle flap for repairing soft tissue defects in middle and lower segments of anterior tibia. *Zhongguo Xiu Fu Chong Jian Wai Ke Za Zhi.* 2016; 30(9):1122-6. DOI: 10.7507/1002-1892.20160228.

## Медіальний литковий клапоть для закриття дефектів тканин у ділянці колінного суглоба

Лябах А.П., Лазаренко Г.М., Кулева О.В.

ДУ "Інститут травматології та ортопедії НАМН України", м. Київ

**Резюме.** Дефекти тканин передньої поверхні голіжки та колінного суглоба є серйозною проблемою при лікуванні пацієнтів з ортопедо-травматологічною патологією. **Мета.** Аналіз результатів застосування медіального литкового клаптя (МЛК) у ортопедо-травматологічних пацієнтів, висвітлення особливостей хірургічної техніки. **Матеріали і методи.** 8 пацієнтів (10 випадків), яким була проведена транспозиція МЛК. Вік пацієнтів становив у середньому 40,5±5,7 року (19-74 років), чоловіків було 6, жінок – 2. Структура випадків: відкриті переломи – 2 пацієнти, бойова травма – 2 пацієнти (3 випадки), некроз шкіри після остеосинтезу – 3 пацієнти (4 випадки), некроз шкіри після ендопротезування – 1 пацієнт. Оцінка результатів лікування була проведена в строки від 9 місяців до 10 років за шкалою Lysholm. **Результати.** Аутодермопластика під час транспозиції МЛК виконана в 2 випадках, в інших – через кілька днів. У випадках відкритих переломів виконували остеосинтез або ремонт АЗФ, конверсію остеосинтезу здійснювали через 1 місяць після аутодермопластики. У випадках некрозу шкіри після остеосинтезу та ендопротезування металоконструкції в жодному випадку не ви-

даляли. Функція колінного суглоба за шкалою Lysholm становила від 70 до 100 балів (у середньому  $88,2 \pm 3,3$  бала). **Висновки.** Транспозиція МЛК для заміщення дефектів тканин передньої поверхні гомілки та колінного суглоба є ефективною методикою в ортопедо-травматологічній практиці, що дозволяє розв'язати проблему інфекційних ускладнень та зберегти опорно-кінематичну функцію нижньої кінцівки.

**Ключові слова:** гомілка; медіальний литковий клапоть; відкритий перелом; дефект тканин.

### **Медіальний икроножный лоскут для закрытия дефектов тканей в области коленного сустава**

Лябах А.П., Лазаренко Г.Н., Кулева А.В.

ГУ "Институт травматологии и ортопедии НАМН Украины", г. Киев

**Резюме.** Дефекты тканей передней поверхности голени и коленного сустава являются серьезной проблемой в лечении пациентов с ортопедо-травматологической патологией. **Цель.** Анализ результатов использования медиального икроножного лоскута (МИЛ) у ортопедо-травматологических пациентов, освещение особенностей хирургической техники. **Материалы и методы.** 8 пациентов (10 случаев), которым была проведена транспозиция МИЛ. Возраст пациентов составил в среднем  $40,5 \pm 5,7$  года (19-74), мужчин было 6, женщин – 2. Структура случаев: открытые переломы – 2 пациента, боевая травма – 2 пациента (3 случая), некроз кожи после остеосинтеза – 3 пациента (4 случая), некроз кожи после эндопротезирования – 1 пациент. Оценка результатов лечения была проведена в сроки от 9 месяцев до 10 лет по шкале Lysholm. **Результаты.** Аутодермопластика во время транспозиции МИЛ выполнена в 2 случаях, в остальных – через несколько дней. В случаях открытых переломов проводили остеосинтез или перемонтаж АЗФ, конверсию остеосинтеза проводили через 1 месяц после аутодермопластики. В случаях некроза кожи после остеосинтеза и эндопротезирования металлоконструкции ни в одном случае не удаляли. Функция коленного сустава по шкале Lysholm составила от 70 до 100 баллов (в среднем  $88,2 \pm 3,3$  балла). **Выводы.** Транспозиция МИЛ для замещения дефектов тканей передней поверхности голени и коленного сустава является эффективной методикой в ортопедо-травматологической практике, которая позволяет решить проблему инфекционных осложнений и сохранить опорно-кинематическую функцию нижней конечности.

**Ключевые слова:** голень; медиальный икроножный лоскут; открытый перелом; дефект тканей.

#### **Відомості про авторів:**

**Лябах Андрій Петрович** – доктор медичних наук, професор, завідувач відділу патології стопи та складного протезування ДУ "Інститут травматології та ортопедії НАМН України", вул. Бульварно-Кудрявська, 27, Київ, 01601, Україна. ORCID: 0000-0001-5734-2392.

**Лазаренко Галина Миколаївна** – кандидат медичних наук, співробітник відділу патології стопи та складного протезування ДУ "Інститут травматології та ортопедії НАМН України", вул. Бульварно-Кудрявська, 27, Київ, 01601, Україна.

**Кулева Олександр Валерійович** – кандидат медичних наук, співробітник ДУ "Інститут травматології та ортопедії НАМН України", вул. Бульварно-Кудрявська, 27, Київ, 01601, Україна.

#### **Information about the authors:**

**Liabakh Andrii Petrovych** – D.Med.Sc., professor, head of the Department of Foot Pathology and Complex Prosthetics, SI "Institute of Traumatology and Orthopedics of NAMS of Ukraine", 27 Bulvarno-Kudriavska St., Kyiv, 01601, Ukraine. ORCID: 0000-0001-5734-2392.

**Lazarenko Halyna Mykolaivna** – Ph.D. in Medicine, the Department of Foot Pathology and Complex Prosthetics, SI “Institute of Traumatology and Orthopedics of NAMS of Ukraine”, 27 Bulvarno-Kudriavska St., Kyiv, 01601, Ukraine.

**Kulieva Oleksandr Valeriovych** – Ph.D. in Medicine, Department of Foot Pathology and Complex Prosthesis, SI “Institute of Traumatology and Orthopedics of NAMS of Ukraine”, 27 Bulvarno-Kudriavska St., Kyiv, 01601, Ukraine.

**Сведения об авторах:**

**Лябах Андрей Петрович** – доктор медицинских наук, профессор, заведующий отделом патологии стопы и сложного протезирования ГУ “Институт травматологии и ортопедии НАМН Украины”, ул. Бульварно-Кудрявская, 27, Киев, 01601, Украина. ORCID: 0000-0001-5734-2392.

**Лазаренко Галина Николаевна** – кандидат медицинских наук, сотрудник отдела патологии стопы и сложного протезирования ГУ “Институт травматологии и ортопедии НАМН Украины”, ул. Бульварно-Кудрявская, 27, Киев, 01601, Украина.

**Кулева Александр Валериевич** – кандидат медицинских наук, сотрудник отдела патологии стопы и сложного протезирования ГУ “Институт травматологии и ортопедии НАМН Украины”, ул. Бульварно-Кудрявская, 27, Киев, 01601, Украина.

**Для листування: Лябах Андрій Петрович**, завідувач відділу патології стопи та складного протезування ДУ “Інститут травматології та ортопедії НАМН України”, вул. Бульварно-Кудрявська, 27, Київ, 01601, Україна. Тел. +38(097)901-03-64. E-mail: [anliabakh@gmail.com](mailto:anliabakh@gmail.com).

**For correspondence: Liabakh Andrii Petrovych**, head of the Department of Foot Pathology and Complex Prosthetics, SI “Institute of Traumatology and Orthopedics of NAMS of Ukraine”, 27 Bulvarno-Kudriavska St., Kyiv, 01601, Ukraine. Tel. +38(097)901-03-64. E-mail: [anliabakh@gmail.com](mailto:anliabakh@gmail.com)

**Для кореспонденції: Лябах Андрей Петрович**, заведуючий відділом патології стопи і складного протезування ГУ “Інститут травматології і ортопедії НАМН України”, ул. Бульварно-Кудрявская, 27, Киев, 01601, Украина. Тел. +38(097)901-03-64. E-mail: [anliabakh@gmail.com](mailto:anliabakh@gmail.com).